

Case Report

Drug Reaction with Eosinophilia and Systemic Symptom in a Patient with Pneumonia and Hyperthyroidism

Hualiang Jin¹, Limin Wang¹, Jian Ye¹

¹Department of Respiratory Diseases, Hangzhou First People's Hospital, Nanjing Medical University, Hangzhou, Zhejiang, China

Received: January 2017.

Accepted: March 2017.

ABSTRACT

Drug rash with eosinophilia and systemic symptoms syndrome is an idiosyncratic drug reaction characterized by fever, skin eruption, lymph node enlargement, and internal organ involvement. We report a case of a patient with pneumonia who developed clinical manifestations of fever, rash, lymphadenopathy, hypereosinophilia, and visceral involvement (renal failure and eosinophilic pneumonitis) caused by methimazole. The patient improved remarkably with drug withdrawal. A high index of clinical suspicion is emphasized to facilitate prompt diagnosis of medication-related adverse effect and its discontinuation.

KEYWORDS: Drug rash with eosinophilia and systemic symptoms, hyperthyroidism, pneumonia, Methimazole

INTRODUCTION

Drug rash with eosinophilia and systemic symptom (DRESS) is a severe adverse drug reaction manifested by a diffuse maculopapular rash, fever, hematological abnormalities, and visceral involvement. Methimazole or thiamazole, together with carbimazole and propylthiouracil, are antithyroid medications belonging to the class of thionamides. Thionamides side effects are rare and include fever, rash, arthralgias, agranulocytosis and hepatitis. To the best of our knowledge, the DRESS syndrome was not reported previously with methimazole (thyrozol) in the Chinese population. Here, we present a case of pneumonia with hyperthyroidism who develop the DRESS with visceral involvement induced by thyrozol.

CASE REPORT

A 78-year-old male was admitted with fever and cough for more than 2 weeks. His medical history was not remarkable, only with mild chronic gastritis. He had not been taking any medication and had not experienced allergies to drugs or food previously. A chest computed tomography (CT) identified multiple patchy on both lungs. On physical examination, the patient presented with crackles in the bilateral inferior pulmonary region. His hematological and biochemical parameters were basically normal, which included a leukocyte count

of $7.2 \times 10^9/L$ (neutrophils 78.2%, lymphocytes 8.3%, and eosinophils 2.6%), aspartate aminotransferase 16 IU/L, alanine aminotransferase 10 IU/L, creatinine 0.67 mg/dL, and C-reactive protein (CRP) 103 mg/L. However, he had a hyperthyroidism condition with FT3 12.43 pmol/L, FT4 65.05 pmol/L, and thyroid stimulating hormone <0.008 mIU/L. Hemoculture, urine culture, and viral serological tests including hepatitis A, B, and C, HIV, Epstein-Barr virus, and herpes virus were all negative. Antinuclear antibody and thyroid antibodies were negative. Abdominal ultrasonography and electrocardiography revealed no remarkable findings.

Based on the clinical examination and CT scan, he was diagnosed of community-acquired pneumonia. He was started with piperacillin-sulbactam (5 g, every 8 h) on the 1st day of admission. Thyrozol (20 mg, every day) was prescribed on day 8 for his hyperthyroidism condition. He got a fever after a bronchofiberscope on day 8. Blood test showed white blood cell count of $20 \times 10^9/L$ (neutrophils 73.3%, lymphocytes 7.3%, and eosinophils 15.3%), CRP 51 mg/L, and procalcitonin 2.22 ng/ml. Piperacillin-sulbactam was stopped, and he was treated with meropenem (1 g, every 8 h) on day 9. However, his fever did not drop down, and

Address for correspondence:

Dr. Jian Ye, E-mail: yejian.med@gmail.com

This is an open access article distributed under the terms of the Creative Commons Attribution-NonCommercial-ShareAlike 3.0 License, which allows others to remix, tweak, and build upon the work non-commercially, as long as the author is credited and the new creations are licensed under the identical terms.

For reprints contact: reprints@medknow.com

How to cite this article: Jin H, Wang L, Ye J. Drug reaction with eosinophilia and systemic symptom in a patient with pneumonia and hyperthyroidism. *J Res Pharm Pract* 2017;6:130-3.

Access this article online

Quick Response Code:



Website: www.jrpp.net

DOI: 10.4103/jrpp.JRPP_17_23

linezolid (0.6 g, every 12 h) was added on to cover gram-positive cocci on day 10 [Figure 1]. On day 12, he developed a maculopapular rash over face, upper trunk, and extremities with facial edema as well as paroxysmal gross hematuria. Biochemical tests showed the following findings: eosinophile was increased to 22.7%, platelet reduced to $113 \times 10^9/L$, and creatinine increased to 2.91 mg/dL, but liver enzymes were normal. At this point, DRESS syndrome was diagnosed as the patient met all 7 RegiSCAR 2 criteria for the DRESS [Table 1].^[1] In view of the temporal relationship and a question regarding thyrozol causing rash, thyrozol was discontinued on the day 13. Moreover, he was initiated to be treated with an

injection of methylprednisolone 40 mg on the day 14, once a day.

Only after 48 h of steroid therapy, the patient started improving symptomatically and the rash gradually resolved. However, the review of CT scan still found multiple patchy on the right lung on the day of 16. Therefore, percutaneous lung biopsy was performed under the guidance of ultrasound. Pulmonary pathology showed lung tissue was infiltrated by lymphocyte and eosinophil with increased interstitial fibrosis and focal granuloma nodule, and periodic acid-Schiff and acid resistance test were negative [Figure 2]. Lung

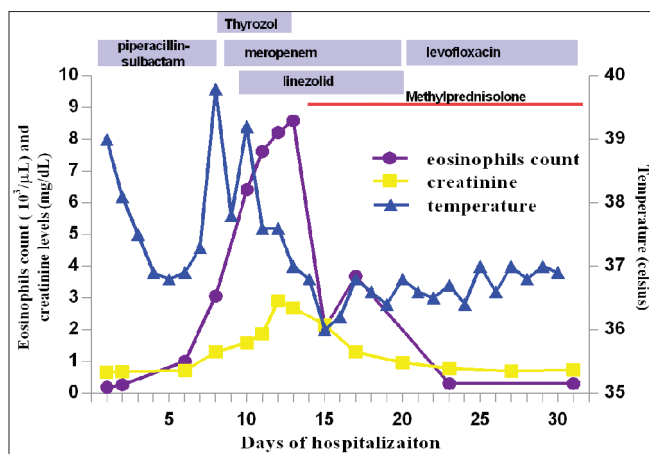


Figure 1: Biochemical and treatment timeline. The graph shows serum creatinine level, eosinophil count, and temperature. Piperacillin-sulbactam was introduced on day 1, and the last dose was received on day 8. Thyrozol was started on day 8 for 6 days. Meropenem was given from days 9 to 20. Linezolid was started on day 10 for 11 days. Conversion factor for serum creatinine in mg/dL to mol/L: 88.4

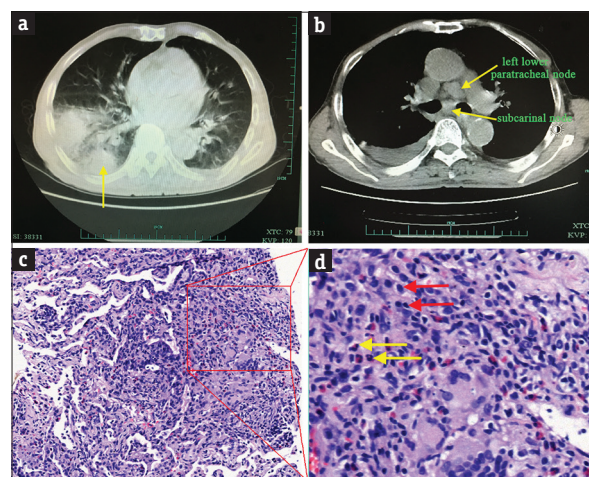


Figure 2: Computed tomography of the chest and lung biopsy. (a) The patchy on right lungs and the puncture site (yellow arrow); (b) Mediastinal lymphadenopathy was seen at left lower paratracheal and subcarinal nodes (yellow arrow); (c and d) Lung biopsy showed infiltration of lymphocyte and eosinophil with increased interstitial fibrosis (H and E, $\times 200$)

Table 1: Scoring systems for diagnosis of drug reaction with eosinophilia and systemic symptom

RegiSCAR study group	Japanese consensus group	Bocquet et al.
More than 3 of the criteria are required for the diagnosis of DRESS	Typical DRESS (presence of all 7 criteria); atypical DIHS (all criteria present except lymphadenopathy and HHV-6 reactivation)	DRESS is confirmed by presence of 1 and 2 and 3
1. Hospitalization	1. HHV-6 reactivation	1. Cutaneous drug eruption
2. Reaction suspected to be drug related	2. Prolonged clinical symptoms 2 weeks after discontinuation of causative drug	2. Adenopathies >2 cm in diameter or hepatitis (liver transaminases >2 times upper limit of normal) (or) interstitial nephritis (or) interstitial pneumonitis (or) carditis
3. Acute rash	3. Maculopapular rash developing >3 weeks after starting drug	3. Hematologic abnormalities
4. Fever above 38°C	4. Fever above 38°C	eosinophilia $>1.5 \times 10^9/L$ (or) atypical lymphocytes
5. Enlarged lymph nodes involving at least two sites	5. Lymphadenopathy	
6. Involvement of at least one internal organ	6. ALT >100 U/L or other organ involvement	
7. Blood count abnormalities	7. Leukocyte abnormalities (at least one)	
Lymphocytes above or below laboratory limits	Leukocytosis ($>11 \times 10^9/L$)	
Eosinophils above laboratory limits (in percentage or absolute count)	Atypical lymphocytosis ($>5\%$)	
Platelets below laboratory limits	Eosinophilia ($1.5 \times 10^9/L$)	

DRESS=Drug reaction with eosinophilia and systemic symptom, ALT=Alanine aminotransferase, HHV-6=Human herpes virus-6, DIHS=Drug-induced hypersensitivity syndrome

tissue culture was also performed with the finding of *Enterococcus faecium* and *Pseudomonas* bacteria. After the treatment with antibiotics and steroid, she gradually recovered and was finally discharged after 34 days in hospital.

DISCUSSION

Various criteria have been evolved to define DRESS; our patient was fulfilling all criteria of RegiSCAR, though he only fulfilled criteria 4, 5, 6, 7 of Japanese consensus group criteria^[2] and criteria 1, 3 proposed by Bocquet *et al.*^[3] Therefore, a diagnosis of DRESS syndrome was established.

Before the onset of the disease, the patient had required different courses of suspect drugs including piperacillin-sulbactam, meropenem, linezolid, and thyrozol. Piperacillin-sulbactam was used for 8 days, and eosinophils count was slightly increased on the day 6. However, at that time the patient had no fever, and with normal hepatic and renal functions. Moreover, the DRESS was induced 4 days after disuse of piperacillin-sulbactam. Therefore, piperacillin-sulbactam was unlikely as the suspect drug. There have been several cases of meropenem or linezolid-induced DRESS.^[4,5] However, the onset of the disease generally ranges from 2 to 8 weeks after the initiation of therapy. In our case, meropenem and linezolid were used no more than 2 days before the onset of the disease. Moreover, these two drugs were continually used for 2 weeks until the syndrome was alleviated by steroid therapy. Therefore, it was unlikely that meropenem or linezolid-induced DRESS. Thyrozol was used for 5 days before the onset of the disease. During the treatment of thyrozol, the patient got fever, and eosinophils count and creatinine level were significantly increased. However, after discontinuation of thyrozol, the temperature, eosinophils count, and creatinine level gradually returned to normal. Suspicion of thyrozol-associated DRESS syndrome, therefore, was based on the clear temporal relationship between the introduction of thyrozol and increase in the temperature, eosinophil count, and acute renal failure. Previous studies have reported cases of drug-induced hypersensitivity syndrome by methimazole.^[6] Besides, other drugs of thionamides class such as carbimazole or propylthiouracil have been reported to induce DRESS syndrome.^[7,8] This case presented here is, to our knowledge, the first case of DRESS following treatment with thyrozol in the Chinese population.

Liver is the most common affected organ in DRESS syndrome. But sometimes, the involved organ can be kidney, lung or heart affected with interstitial nephropathy, pneumonitis, pericarditis or myocarditis.^[9] Interestingly, our patient was presented with normal liver

function. However, he had gross hematuria and increased high level of creatinine, indicating the acute renal failure. Pulmonary pathology showed lung tissue was infiltrated by eosinophil and lymphocyte and presented with increased interstitial fibrosis. Lung tissue culture was found with *E. faecium* and *Pseudomonas* bacteria. These results suggested that due to the DRESS, the patient had bacterial pneumonia followed with eosinophilic pneumonitis, which led to the slow absorption of pneumonia.

The most common differential diagnoses include hypereosinophilic syndrome, Sezary syndrome, and Stevens–Johnson syndrome whose diagnostic criteria are very similar to those of DRESS syndrome. Hypereosinophilic syndrome is a condition with blood eosinophilia of greater than 1500/mm³ for about 6 months but without a discernable secondary cause. Sezary syndrome often presents with skin lesions that do not heal with normal medication. Stevens–Johnson syndrome is a milder form of toxic epidermal necrolysis commonly with cutaneomucous erosions. In this case, blood eosinophilia was at normal level before the patients' admission, and his symptom was possibly associated with the drug. The skin pattern of our patient was maculopapular rash without mucous erosions, and his skin lesions were alleviated by corticosteroids. Thus, these differential diagnoses could be ruled out.

So far, prompt withdrawal of the offending drug is the undisputed way to treat the DRESS, and systemic corticosteroids may alleviate a variety of clinical symptoms and prevent tissue damage.^[10] Further research is still needed, as the ideal dosage of corticosteroids and the length of therapy are unknown.

AUTHORS' CONTRIBUTION

Hualiang Jin was responsible for idea and draft writing for the manuscript. Limin Wang was responsible for literature search as well as draft writing for the manuscript. Jian Ye was responsible for the overall supervision of the editing, manuscript writing, as well as all the support for literature search and providing resources.

Financial support and sponsorship

This work was financially supported by Zhejiang Provincial Medical and Health Science and Technology Plan (No.2014KYA170).

Conflicts of interest

There are no conflicts of interest.

REFERENCES

1. Kardaun SH, Sidoroff A, Valeyrie-Allanore L, Halevy S, Davidovici BB, Mockenhaupt M, *et al.* Variability in the

- clinical pattern of cutaneous side-effects of drugs with systemic symptoms: Does a DRESS syndrome really exist? *Br J Dermatol* 2007;156:609-11.
2. Shiohara T, Iijima M, Ikezawa Z, Hashimoto K. The diagnosis of a DRESS syndrome has been sufficiently established on the basis of typical clinical features and viral reactivations. *Br J Dermatol* 2007;156:1083-4.
 3. Bocquet H, Bagot M, Roujeau JC. Drug-induced pseudolymphoma and drug hypersensitivity syndrome (Drug Rash with Eosinophilia and Systemic Symptoms: DRESS). *Semin Cutan Med Surg* 1996;15:250-7.
 4. Prados-Castaño M, Piñero-Saavedra M, Leguísamo-Milla S, Ortega-Camarero M, Vega-Rioja A. DRESS syndrome induced by meropenem. *Allergol Immunopathol (Madr)* 2015;43:233-5.
 5. Savard S, Desmeules S, Riopel J, Agharazii M. Linezolid-associated acute interstitial nephritis and drug rash with eosinophilia and systemic symptoms (DRESS) syndrome. *Am J Kidney Dis* 2009;54:e17-20.
 6. Ozaki N, Miura Y, Oiso Y. A case of type 1 diabetes followed by methimazole-induced hypersensitivity syndrome. *Diabetes Care* 2006;29:1179-80.
 7. Vinzio S, Goichot B, Andrès E, Schlienger JL. Hypersensitivity syndrome: A rare but severe adverse effect of antithyroid drugs. *Ann Endocrinol (Paris)* 2000;61:151-3.
 8. Ye YM, Kim JE, Kim JH, Choi GS, Park HS. Propylthiouracil-induced DRESS syndrome confirmed by a positive patch test. *Allergy* 2010;65:407-9.
 9. Criado PR, Avancini J, Santi CG, Medrado AT, Rodrigues CE, de Carvalho JF. Drug reaction with eosinophilia and systemic symptoms (DRESS): A complex interaction of drugs, viruses and the immune system. *Isr Med Assoc J* 2012;14:577-82.
 10. Shiohara T, Kano Y. Drug reaction with eosinophilia and systemic symptoms (DRESS): Incidence, pathogenesis and management. *Expert Opin Drug Saf* 2017;16:139-47.